

Hemostatic Damage Control Surgery Combined with Strategic Evacuation in an Intensive Care Airborne Unit Saved Life in a Critical Gun Shot Injury

LtCol Johan Pillgram-Larsen, MD,
Chief Consultant in Surgery, Norwegian Defense,
Department of Cardiothoracic Surgery,
Ullevål University Hospital,
N-0407 Oslo, Norway

pillgram@hotmail.com / jopl@uus.no

Christine Gaarder, MD,
Trauma Research Fellow
Specialist in Gastrointestinal Surgery,
Department of Gastrointestinal Surgery,
Ullevål University Hospital,
N-0407 Oslo, Norway

LtCol Karlheinz Fuchs, MD,
Chief of Aeromedical Evacuation,
German Armed Forces,
LTKdo – Abt Kommandoarzt,
Manfred v Richthofen Strasse 8
D-48145 Münster, Germany

DAMAGE CONTROL AND STRATEGIC EVACUATION

A Norwegian officer was shot and critically wounded in Afghanistan in 2003. His life was primarily saved by damage control surgery in a Dutch military hospital in Kabul. He was evacuated with an intensive care air transport from Kabul, via Termez to Oslo, Norway, where final surgery was performed. He has recovered. The case demonstrates how advanced damage control surgery in the area of operation combined with an organization equipped and staffed for strategic evacuation of intensive care patients can offer treatment to combat casualties on the level of western urban trauma care.

1.0 INTRODUCTION

The first priority in trauma care is to maintain oxygen delivery by stopping hemorrhage, if necessary by early emergency surgery and damage control. Damage control is a three step procedure: ¹⁾ Transport without delay to a surgical facility where the hemorrhage is stopped by operative packing without final repair before the patient becomes cold and acidotic and develops bleeding disorders; ²⁾ Intensive care with normalization of the hemostasis; ³⁾ Definitive, reparative surgery [1]. This procedure for handling critical bleeding has been seen to improve survival [2, 3]. The present case story from the International Security and Assistance Force (ISAF) in Afghanistan demonstrates the concept.

Paper presented at the RTO HFM Symposium on “Combat Casualty Care in Ground Based Tactical Situations: Trauma Technology and Emergency Medical Procedures”, held in St. Pete Beach, USA, 16-18 August 2004, and published in RTO-MP-HFM-109.

2.0 PATIENT

On the 13th May 2003 a Norwegian major, a 44 year old male, on CIMIC duty 20 km north of Kabul in Afghanistan was hit by a shot fired from a Kalashnikov AK47 at a distance of 60 meters.

The entry wound was in the back of the chest, just to the right of the spine. The lower lobe of the right lung was lacerated. The exit wound low anterolateral in the right chest was half the size of a palm. Two ribs were crushed. The missile had touched the top of the diaphragm and left a 7 cm long laceration. There were multiple lacerations in the liver going from dome all through the parenchyma to the hilum (Organ Injury Scale grade IV [4] (figure 1).

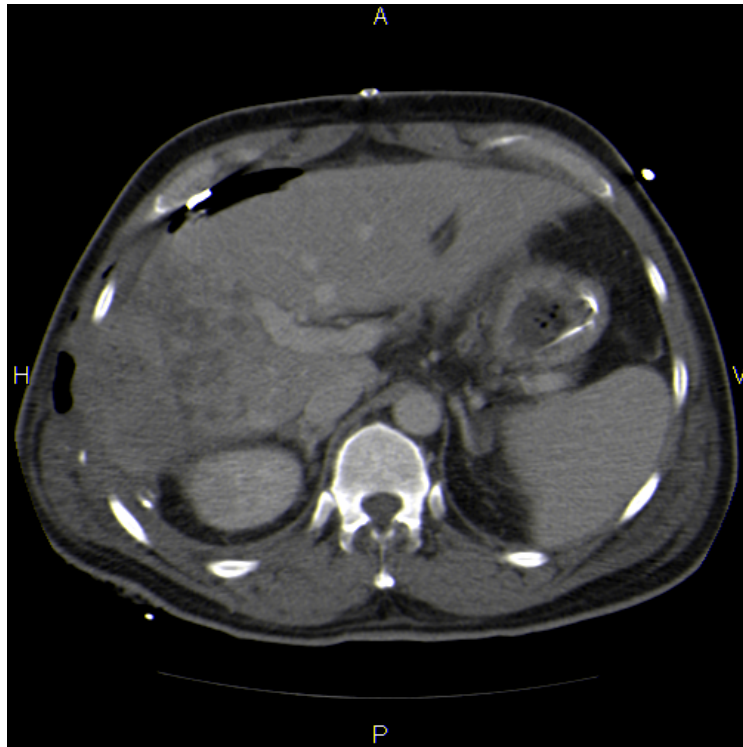


Figure 1: The crushed liver with hemostatic packing as it was be Demonstrated by CT on arrival in the trauma center three days post trauma. Multiple lacerations from the dome of the liver down to the hilum can be seen.

3.0 CLINICAL COURSE

The patient was evacuated by a German helicopter manned by a flight surgeon, medic, ICU nurse and anesthesiologist to a role 2+ facility run by the Dutch at the international airport in Kabul. The victim was hit 1145 and moved out of the area of danger. Medevac was requested 1155. The helicopter was alerted 1210, was on scene 1230, left the scene 1250. On site the patient was responding. He was pale, in pain and with an increased pulse rate. The patient arrived in ER 1310. BP was then 150/80, HR 85, SaO₂ 95% with 10 liters of Oxygen. A chest drain produced 300 ml. He was brought to operation 1340. Laparotomy was performed by surgeons LCCDR Idenburg, MAJ Massagè, MAJ Bille and with COL van Aggelen in charge of anesthesia. Control of profuse bleeding from the liver was achieved by compression and packing. The exit wound was left open. Next day the rupture of the diaphragm was sutured to facilitate more effective repacking. Sharp edges of the ribs were resected.

He was kept on a ventilator. Hemoglobin dropped to 5,5 mmol/l and he was transfused with two units of erythrocytes.

The third day post trauma the patient was evacuated from Kabul. He was first taken to Termez in Uzbekistan by a C160 Transall transport plane with intensive care capacity. In Termez the patient was transferred to a German Airbus A310 Multi Role Transporter and flown to Oslo, Norway (figure 2).

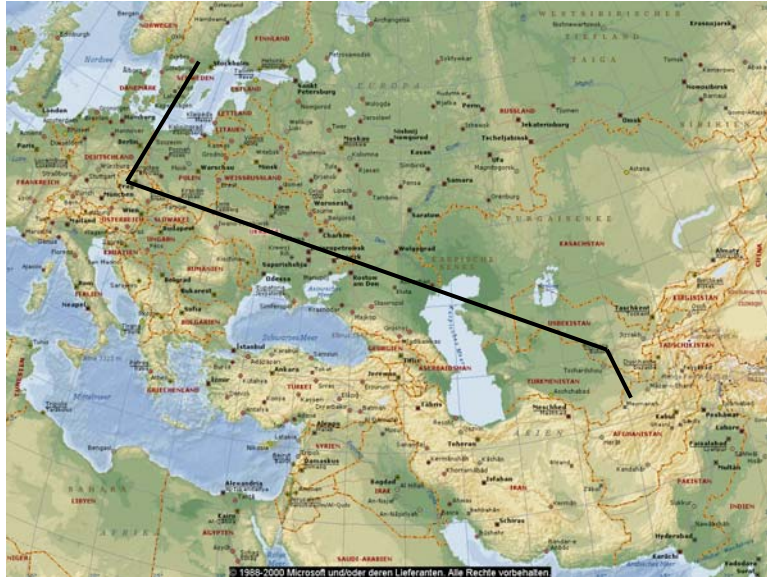

Figure 2: The distance from Kabul to Oslo is more than 6000 km, in part over mountainous and deserted areas.

The Airbus 310 has the capacity of lifting 44 patients in a whole, 6 of them under intensive care ventilator therapy and the rest under intensive care monitoring and treatment. The plane is staffed with 25 nurses and doctors (figure 3 and 4]. From Oslo Airport to Ullevål University Hospital the patient was transported in an intensive care ambulance staffed and equipped for all types of intensive care including extracorporeal circulatory support.



Figure 3: The German Air Force Airbus A310 Multi Role Transporter has a range of 9540 km and can evacuate patients to virtually any destination in the world. It is available at any time.



Figure 4: The Air Force Airbus A310 Multi Role Transporter equipped for intensive care treatment can carry 44 patients, 6 on ventilator treatment.

On the night of arrival in Oslo angiography revealed no ongoing hemorrhage. At relaparotomy the packing was removed, the wounds revised. Repeated wound revisions were necessary. The entry and exit wounds were left to granulate. He suffered infectious complications and pulmonary insufficiency. There was biliary leakage. He spent three weeks under intensive care and was discharged after two months. He is now rehabilitated (figure 5).

4.0 DISCUSSION

Damage control surgery in a forward area is an option when hemorrhage is too severe to permit evacuation to a larger surgical installation further back where intensive care facilities exist. The surgical problems of damage control surgery may be overcome in a forward field hospital. However, by introducing damage control surgery in forward areas intensive care patients are created. The bleeding may be arrested, but the problem of getting an intensive care patient out remains [5].

To succeed in damage control lifesaving surgery, all links in the chain of the treatment must be understood, from the first responder through to the surgeons doing the final repair. Time must not be wasted before surgery. Low-pressure fluid resuscitation is recommended. When the hemorrhage has been controlled, time is available to stabilize the patient and organize the evacuation with expert support. A trained organization must be in place.

Ideally we would prefer to do final repair as soon as the patient is hemodynamically stable, usually after 24 to 36 hours. In this case it took some time to arrange the evacuation. The patient was Norwegian. The organization that undertook the evacuation is German. There are no automatic routines for one nation to undertake strategic patient evacuation for another. All administrative problems were however smoothly solved. For a small nation it is unrealistic to maintain a complete organization for strategic evacuation. In areas where there are no security risks the Norwegian military rely on the civilian "Norwegian Air Ambulance" for intensive care transports. This firm cannot be used in areas with ongoing hostilities. It seems rational to leave strategic evacuation to one lead nation. But in future international operations a binding, detailed agreement on this should be in place and the military command must have detailed knowledge on how to activate the service.

In our courses in war surgery training on an animal model is practiced with the primary goal to disseminate knowledge about damage control surgery. We are encouraged by this case story and see it as an argument in support of the concept. It is important to consider the surgical and intensive care and the

transportation as complementary parts. A system for strategic evacuation on permanent standby is expensive. The decision to implement the training and maintain the organization will be a political one.

5.0 CONCLUSION

With training and an understanding of the importance of early hemostatic damage control surgery and backed by an organization equipped and staffed for strategic evacuation of intensive care patients, critical combat casualties may be given treatment on the level of western urban trauma care.



Figure 5: In a newspaper interview six months post trauma the patient expressed the wish to volunteer for a new mission, although discouraged by his spouse and daughter.

6.0 REFERENCES

- [1] Rotondo MF, Schwab CW, McGonigal MD, Phillips GR, Fruchterman TM, Kauder DR. "Damage control": an approach for improved survival in exsanguinating penetrating abdominal injury. *J Trauma*. 1993;35:375-383.
- [2] Johnson JW, Gracias VH, Schwab CW, et al. Evolution in damage control for exsanguinating penetrating abdominal injury. *J Trauma*. 2001;51:261-271.
- [3] Nicholas JM, Rix EP, Easley KA, et al. Changing the patterns in management of penetrating abdominal trauma: the more things change, the more they stay the same. *J Trauma*. 2003;55:1095-1110.
- [4] Moore EE, Cogbill TH, Jurkovich GJ, Shackford SR, Malangoni MA, Champion HR. Organ injury scaling: spleen and liver (1994 revision). *J Trauma*. 1995;38:323-324.
- [5] Eiseman B, Moore EE, Meldrum DR, Raeburn C. Feasibility of damage control surgery in the management of military combat casualties. *Arch Surg*. 2000;135:1323-1327.

